National Academy of Opticianry

ANATOMY & PHYSIOLOGY OF THE EYE

Approved by the ABO and NCLE

COPYRIGHT 2025 by the National Academy of Opticianry. All rights reserved. This book, or parts thereof, may not be reproduced in any form or by any means, electronic or mechanical, including photocopy, recording, or any information storage and retrieval system now known or to be invented, transmitted in any form or by any means electronic or mechanical without the expressed prior written permission of the copyright owner. For information, please contact the National Academy of Opticianry, 8401 Corporate Drive #605, Landover, MD 20785.

Anatomy & Physiology of the Eye

Authors:

Course Level:
Advanced – Level II

Course Length:
Two hours

Course Description:

Anatomy and Physiology of the Eye will list and identify the basic structures of the eye, explaining the visual functions of each. The three tunics of the eye will be discussed. Included will be external as well as internal structures, adnexa, and the bony orbit as well as muscles of the eye.

Instructional Objectives:

At the completion of this course, the participant will be able to:

- List the external structures of the eye
- Identify the 3 tunics of the eye
- Identify the basic ocular structures of the eye
- Explain the visual functions of the basic structures of the eye
- List the layers of the cornea
- List the 6 extraocular muscles
- Describe the primary functions of the 3 tunics of the eye

Anatomy and Physiology of the Eye

Introduction

The eye is an incredible organ. According to the Vision Council, it has been found that 80% of all learning is accomplished from vision during the first 12 years of a person's life. That's huge. With that in mind, we find that it's important that we understand the structures of the human eye and how they work. This course is only the beginning of your education on the anatomy and physiology of the human eye because learning comes in stages. There is certainly more to learn, and we hope that you will continue to strive to learn as much as possible about this wonderful organ. This course will discuss the major parts of the eye and their functions.

The following topics will be presented in this course.

- External structures of the eye
- Internal structures
- Basic ocular structures of the eye
- The primary function of the structures of the eye
- 3 tunics of the eye
- Muscles of the eye

Physical Dimensions of the Globe and Cornea

The average physical diameter of the globe of the eye is about 24.0 mm in a normal eye. That is based upon a radius of 12 mm. So, as you can see the globe is almost round. Added to that, the average cornea protrudes approximately 2.5 mm. By combining the length of the globe and the cornea, the axial length of the average eye is about 26.5 mm. Of course, we know that there are variables in all eyes, but these numbers are averages.

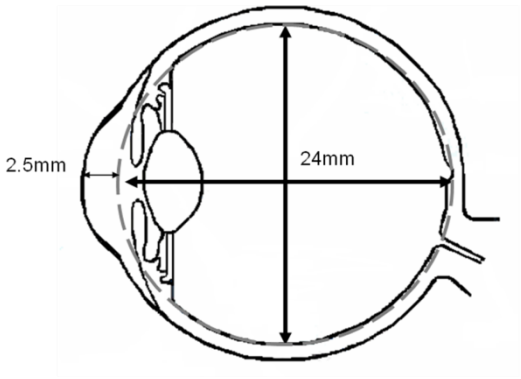

Extraocular Structures/Adnexa

The extraocular structures of the eye include the eyelids, the orbit, and the lacrimal glands. Detailed below are the protective extraocular anatomy.

These are structures that are outside of the eye, itself, protecting the eye.

Eyebrows
Eyebrows help shield the eye from strong light. As you will notice, the hair grows laterally so that they protect the eye from perspiration from running into the eye. The arch shape of the eyebrow diverts rain or sweat down our cheeks, keeping our eyes dry. Oils produced from the sebaceous glands help to protect the eye. Also, as many of us remember from our mothers, eyebrows also help to give facial expressions. Who among us doesn't remember those expressions with the raised eyebrows from our Moms? Speaking with the eyes is part of communication.

The movements of the eyebrows are performed by the Frontalis Muscle. It is the brow's muscle. It lifts the eyebrow out of the way and is a muscle of facial animation. Starting at the top of the head, it attaches to the eyebrow skin. Secondarily, it can lift the eyelid in a secondary fashion and helps to compensate for eyelid muscles to a certain degree. As a person ages, the Frontalis Muscle, just like all muscles, loses tautness, and the brow will begin to somewhat sag.

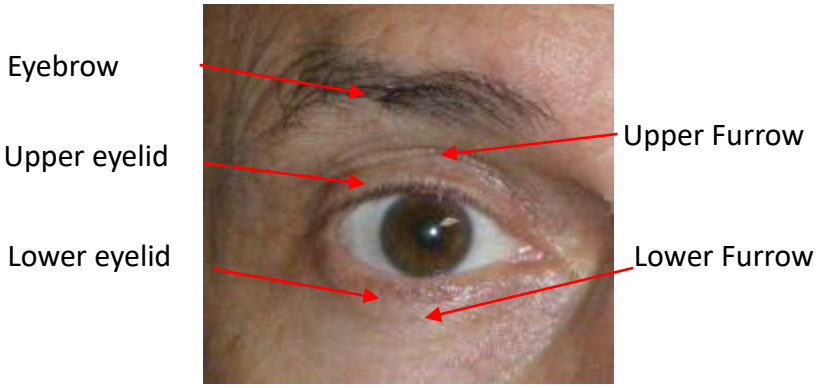

Eyelids
The eyelids are important in eye health. Their primary functions are to help keep the eye moist through the blinking action and protection of the eye. They help to rewet the corneal and conjunctival surfaces with the tear film. The blinking is not just up and down, but rather the eyelids blink from temporal to nasal, creating a type of circular action with the tears to help distribute tears, oxygen, and nutrients as well as flush dirt and debris out of the eye toward the inner canthus for easy removal.

If the cornea is exposed or not lubricated properly, epithelial defects, such as scarring, vascularization, or infection can occur. Results could include ocular irritation, pain, and loss of vision. Eyelid closure distributes tears over the surface of the eye and pumps them through the

lacrimal puncta into the tear duct. Excessive tearing or epiphora (tearing which results in tears overflowing onto the face) may result from various eyelid disorders.

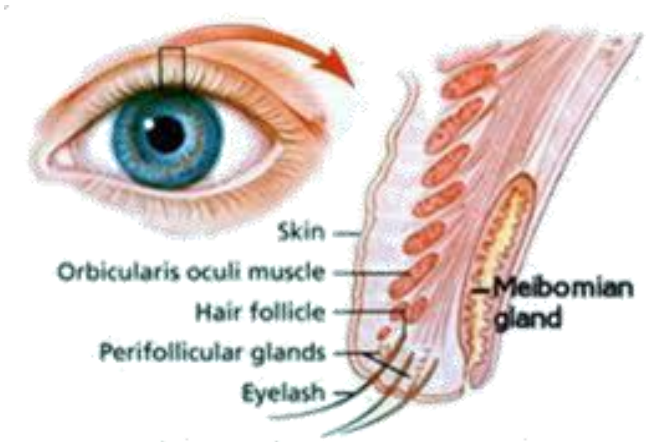

Also called palpebrae, the eyelids are folds of tissue that protect the eye and provide tear and oxygen distribution to the eye. When opened, the eyelids form the palpebral aperture. It is interesting to note that they are not always the same size. During an examination or prefit evaluation, the aperture size is important and should be noted on a patient's record. Any abnormal difference in size or position should also be noted. We'll discuss the tissues of the eyelids in a moment, but right now will only mention that they contain oil-producing glands; the meibomian glands, and the sebaceous glands (the glands of Zeis). The gland of Moll, a sweat gland, is also a lipid secretor.

The muscles of the eyelids create the motor system of the eyelids. They are the levator muscle/levator palpebrae superioris, the orbicularis oculi muscle, and Muller's muscle. Movements of these muscles may be either voluntary or involuntary.

The Levator Palpebrae Superioris muscle originates in the inferior aspect of the lesser wing of the sphenoid bone. Its primary function is to elevate and retract the upper eyelid. It has some function in pumping tears away.

The Orbicularis Oculi Muscle originates at the medial orbital margin and lacrimal sac (orbital, palpebral, and lacrimal parts). Its primary function is to close the eyelids and aid the passage and drainage of tears.

Muller's Muscle is a short muscle controlled by the sympathetic nerves. It is generally contracted while awake so that it lifts the eyelid. When tired or asleep, it is relaxed letting the eyelid sag and droop.

The Bony Orbit

The bony orbit serves as a protective socket for the eyeball & associated muscles, nerves, vessels, lacrimal apparatus & supportive orbital fat. It is composed of seven bones; the maxilla, the palate, the frontal, the sphenoid, the zygomatic, the ethmoid, and the lacrimal bones.

The bony orbit creates a quadrangular pear-shaped structure whose stem lies in the depths of the medial wall & a base that faces forward, laterally & slightly downward. Forward is the globe of the eye and the rear is at the optic canal.

Contents of the bony orbit include the muscles, nerves, vessels, fatty tissues, and the eyeball, itself. We will discuss these later.

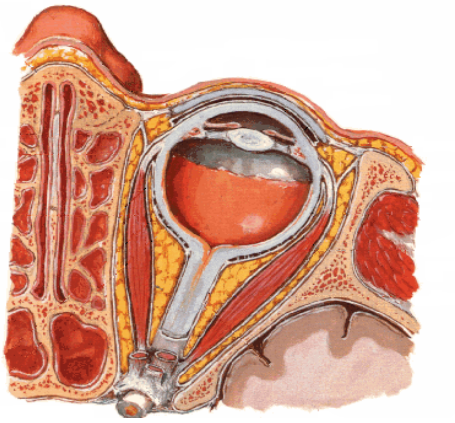

The bony orbit is divided into four main parts: the roof, the medial wall, the orbital floor, and the lateral wall.

The average size of the orbital margin in adults is 35 mm vertically and 40 mm horizontally.

Changes can occur with the development of the bony structure with age. Sinuses also influence the changes in the orbit.

It should also be mentioned that trauma will influence the bony orbit and therefore placement of the contents, including the eyeball itself. Injuries/trauma can affect the alignment of the eyes, affecting vision. Diplopia can occur, amid other complications.

Other influences that can affect the shape of the bones, and the bony orbit, include having patients who are bedridden and are immobile. Long-term positions on the side or the back can change the shape of the entire skull and affect the bony orbital bones, affecting the alignment of the eyes.

Lacrimal Apparatus - Tear Production

Reflex Tear Secretion
Lacrimal glands provide reflex tear secretion. These reflex tears, only flow periodically and require some stimulus; as in irritation such as fumes in the air when peeling an onion, etc., when coughing or sneezing, when tasting something hot or spicy or smelling something strong, during an emotional experience, such as watching a sad movie, before they begin to flow. However, reflex tears usually stream out of the eye and down the cheek and contain mostly water and have very little lubricating mucous/mucins or lipids in them, and evaporate very quickly, therefore are not useful as a quality tear film. The excessive tearing complaints of some dry eye sufferers

result from the eye's attempt to compensate for the lack of lubricating tears, which are more often deficient in the dry eye condition. Reflex tears flow as the eyes attempt to compensate for the irritation caused by the lack of lubricating tears. Newborns have a minimal output of reflex tears, which is why newborns can cry frequently, with no tears flowing.

Basic Tear Secretion

Basic tear secretion is produced by the glands of Wolfring and Krause. These are the lubricating tears or tear film, known as the basal/basic tear secretion or the steady state, and are made up of lipids/oils, aqueous/water, and mucins/mucous. These flow constantly across the surface of the eye, bathing it in moisture and protecting it from exposure. The lubricating tear film normally spreads smoothly over the corneal surface with each eyelid blink. With dry eyes and the associated rapid break-up of the corneal tear film, one complaint of dry-eyed individuals is a momentary blurring of vision that improves with blinking. Lubricating tears also protect the eye from infection, since they contain several anti-bacterial substances. For this reason, severely dry-eyed patients should avoid contact lens wear, which promotes additional drying and increases the risk of infection further.

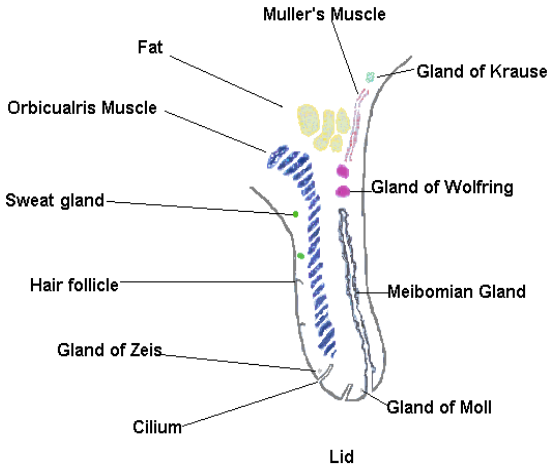

Normal tears contain various antibacterial and immune substances to clean and protect the eyes. The aqueous layer, which is the middle layer of the tear film and is referred to as the water layer, contains inorganic salts, glucose, and urea, as well as biopolymers, proteins, and glycoproteins. Because aqueous production is depressed in patients with tear deficiency, many patients frequently suffer from blepharitis and other lid and eye disorders.

After lubricating, and nourishing the eye, the tears drain out of the eye through the lacrimal puncta in the canaliculi, which are the tear canals, and into the nose or down the throat through the lacrimal duct. Many practitioners find it beneficial when instilling fluorescein into a patient's eyes to explain this drainage to them, so they won't be alarmed when they blow their nose and see the yellow color. Many of you have probably experienced tasting drops/medications that were instilled in your eyes as well.

Lacrimal Apparatus
Tears form a thin film over both the cornea and the conjunctiva. It creates a tear meniscus/prism/lake on the lower lid margin, as shown below. As the upper lid closes and meets the lower lid, it brings with it the tear film to spread across the cornea and conjunctiva. It is important to evaluate this tear meniscus to assist in assessing tear quantity and quality. It should be clear with no bubbles or frothing and of sufficient quantity.

A patient who experiences ectropion, meaning the eyelids are turned outward, will not have a lid margin for the tears to rest on and the tears will spill over and run out of the eye. Furthermore, the opposite of ectropion is entropion, whereby the eyelids are turned inward and will cause discomfort if not damage to the cornea and sclera as the eyelashes will be in contact with the eyeball, itself. We will discuss this condition a little more later on.

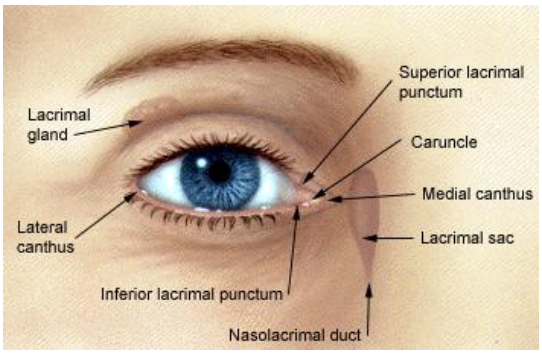

Tears move upward and downward with each blink. The blinking action spreads tears over the entire eye and conjunctiva. The movement is from temporal to nasal. If the movement were merely up and down, the tears would not distribute evenly, nor would waste product be moved from the eye and to the inner canthus.

Tear Film / Precorneal Tear Film

As we have discussed the film some up to this point, let's discuss it more in-depth now.

The tear film, more correctly called the precorneal tear film, provides a smooth optical surface over the cornea. It flushes away cellular debris and foreign matter from the cornea and conjunctival sac as well as carbon dioxide. It provides nutrition for the cornea and provides the antibacterial function that we have discussed previously.

In reality, the tear film or precorneal tear film, also called the tear layer, is the first refracting medium of the eye. It offers a smooth optical surface to the cornea for light to pass through.

There are three layers to the tear film / precorneal tear film. The outermost layer is the lipid or oily layer, the middle layer is the aqueous or water layer, and the innermost layer is the mucin or mucous/mucoid layer.

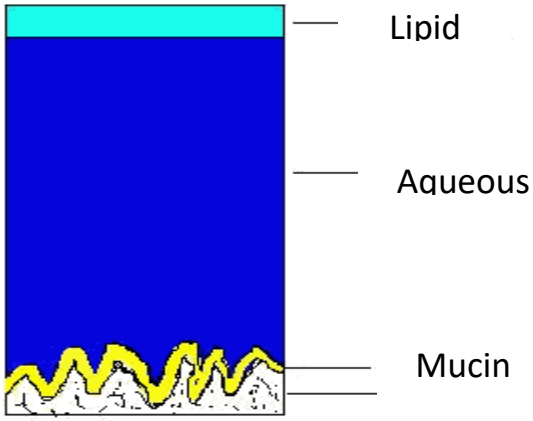

Tear Layer

Outer Layer – Oily
The outermost layer of the tear film is the lipid layer or oily layer. It is secreted by the meibomian glands, which are located within the eyelids, with openings on the lid margins, and the accessory sebaceous glands of Zeis. The function of the lipid layer is to prevent evaporation of the aqueous portion of the tears.

Middle Layer - Aqueous
The middle layer is the aqueous layer or water layer and is secreted by the lacrimal glands and the accessory glands of Krause and Wolfring. As previously mentioned, the aqueous layer is the thickest layer of the tear film. In addition to water, it contains oxygen and nutrients that help to nourish the eye as well as antibacterial components to keep the eyes free of bacteria. It maintains hydration of the corneal surface.

Inner Layer – Mucin/Mucoid/Mucous

The innermost layer of the tear film is the mucoid layer. It is also referred to as the mucous layer or mucin layer. It is produced by goblet cells, which are located in the conjunctiva.
The primary functions of the mucin layer are to attach tears to the cornea and to decrease surface tension. The mucin adheres to the microvilli on the corneal surface and creates a hydrophilic surface to which the aqueous layer attaches. This is achieved through the act of blinking. As the lids open in the relaxation phase of the blink, the high surface tension at the air-aqueous layer interface facilitates a rapid spread of the oily/lipid layer. As the tear film is decreased by evaporation between blinks, the oily superficial layer becomes admixed with the mucinous film, recreating the hydrophobic state of the corneal epithelium and favoring the breakup of the tear film. Each blink aids in maintaining normal wetting of the cornea by spreading the mucin layer.

Normally the tear breakup time (BUT) is longer than the interval between blinks and no corneal drying takes place. A deficiency in conjunctival secretion could produce" dry eye" symptoms even in the presence of an adequate tear component.

Conjunctiva

The Conjunctiva is a mucous membrane (because it contains cells that produce mucus) that runs continuously from the limbus to the lid margin. It contains goblet cells which produce the mucin for the tear layer. It also contains the glands of Wolfring and Krause. On the lids, it is referred to as the palpebral conjunctiva, while on the globe of the eye; it is referred to as the bulbar conjunctiva. Where it joins in the inferior and superior fornix, it is called the fornical conjunctiva. It is highly vascular.

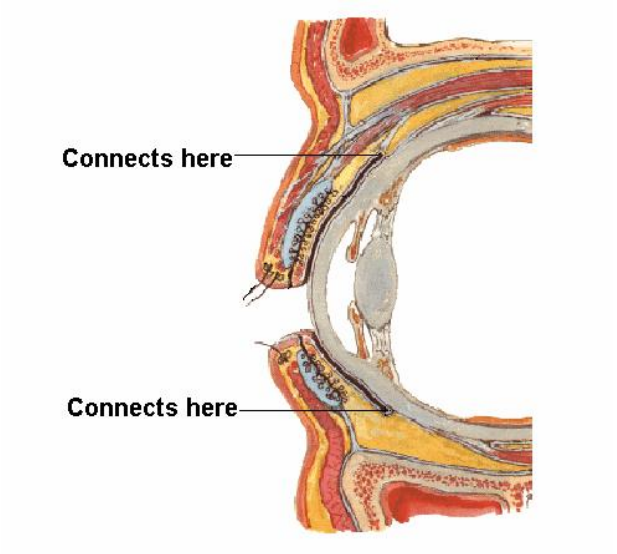

The conjunctiva can become inflamed (known as conjunctiva) because of bacteria, a virus, an allergic reaction, or a chemical burn. Conjunctivitis symptoms such as pain, photophobia (light sensitivity), impaired vision, and discharge. The type of discharge helps to identify the type of conjunctivitis. It has a great blood supply that becomes injected when the conjunctiva is

inflamed. The conjunctiva is also highly innervated, which is why damage or irritation causes much discomfort.

Three Tunics /Coats

There are three tunics, also referred to as three coats of the eye. They are:

- Outer tunic – Fibrous tunic
- Middle tunic – Vascular tunic
- Inner tunic - Retina

Outer Tunic – Fibrous Tunic
The outer tunic, which is the outer protective coat of the eye, is a fibrous tunic. It consists of the cornea, the sclera, and additionally the corneal/scleral junction, which is the limbus. The cornea is transparent and avascular (without blood vessels). It forms the anterior 1/6 portion of the eye. The sclera is opaque and constitutes the posterior 5/6 of the tunic. The limbus is the junction of the meeting of the cornea and the sclera.

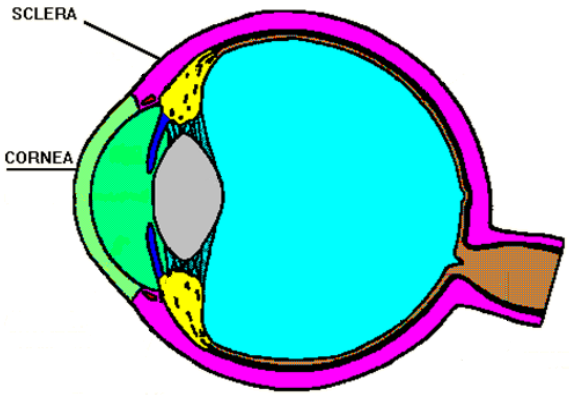

Sclera
The sclera is the white of the eye. "Don't shoot until you see their scleras ". The exterior is smooth and white, being comprised of fibrous tissues. It is opaque, preventing light from entering the eyeball.

The Cornea
For clear vision to take place, the cornea must have regular cell structure, must remain avascular, must be free of scarring, have adequate oxygen, and must maintain sufficient hydration without being overly hydrated. The cornea is the clear bulging surface in front of the eye. It is the main refractive structure of the eye having a power of between 42.00 D to 45.00 D of power. It has an index of refraction of 1.37. It is highly innervated and is extremely sensitive. This sensation diminishes with age and is a result of desensitizing due to the loss of oxygen to the eye. Contact lens wear may decrease the sensation of the cornea. In addition, many patients with diabetes have decreased sensation of the cornea. The cornea receives nutrition from the aqueous humor and the precorneal tear layer.



There are 5 distinct layers of the cornea. Beginning from the outermost layer they are in order, the epithelium, Bowman's layer, stroma, Descemet's membrane, and the endothelium.

The epithelium is approximately 5-7 cell layers thick and is constantly renewed. It provides a barrier to the cornea against external microorganisms. A break in the surface will allow microorganisms to enter the cornea, causing infection, possibly leading to vision loss. Previously called Bowman's membrane, Bowman's layer is a noncellular layer that is extremely tough. It will not regenerate, and while it is very tough, any damage to Bowman's layer will result in a scar. The middle layer of the cornea is the stroma, which comprises approximately 90% of the thickness of the cornea. It is made up of finely layered collagen fibrils regularly stacked lamellar cells. The next layer is Descemet's membrane. Descemet's membrane is comprised of two layers and will retain the shape of the stroma when changes occur due to edema or other causes of corneal shape alteration. It is not very tough but will regenerate after injury. The innermost layer of the cornea is the endothelium. The endothelium is a single layer of regularly sized, hexagonally shaped cells. They do not regenerate when lost/die. The primary function of the endothelium is to pump fluids and waste out of the cornea and to allow nutrients from the aqueous humor to nourish the cornea. Loss of endothelial cells compromises the integrity of the structure, thereby reducing its efficiency. When fluid accumulates in the cornea causing edema, it is stored between the layers of cells in the stroma. This fluid pushes the finely stacked cells apart causing irregular cell structure and thus causing blurry vision. Corneal edema may develop to the point where the surface epithelium forms blisters that intermittently rupture, causing sharp pain - a condition termed Bullous Keratopathy.

Limbus

The limbus is approximately 1mm wide and is located at the corneo/scleral junction and is the highly vascular transition zone between the avascular cornea and the highly vascularized conjunctiva. Limbal blood vessels help to nourish and oxygenate the cornea since the cornea should remain avascular. Vessels should be seen to just penetrate the cornea and loop back towards the conjunctiva.

The canal of Schlemm encircles the limbal region, which is where the aqueous drains into the trabecular meshwork. This is important in the prevention of glaucoma. We'll discuss this more in the chapter on conditions of the eye.

Middle Tunic

Being the middle layer, this layer is located between the sclera and the retina. It is the vascular layer of the eyes. Also referred to as the vascular tunic; the Uvea or Uveal tract contains the choroid, the ciliary body, and the iris.

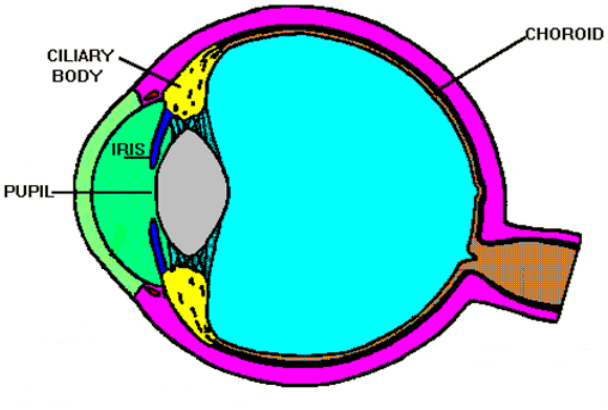

The iris divides the anterior compartment, the space separating the cornea and the lens, into the anterior chamber (between the cornea and the iris) and the posterior chamber (between the iris and the lens).

The choroid is rich in blood vessels and stretches from the optic disc in the back of the eye to the ora serrata toward the front of the eye. Its thickness varies from 0.1 mm to 0.2 mm.

Ciliary Body
The anterior portion of the middle tunic is the ciliary body, which is a triangular section between the choroid and the root of the iris, consisting of the ciliary muscle, and the ciliary processes.

The ciliary processes are highly vascular and contain lymphatic spaces. This is the area of the production of aqueous humor.

The ciliary muscle system controls change in the crystalline lens for accommodation. The ciliary muscle contracts to look at distant objects and releases tension to look at near objects (accommodation). Presbyopia occurs when the crystalline lens becomes less elastic, in addition to other age-related changes which will be discussed later during our discussion of presbyopia.

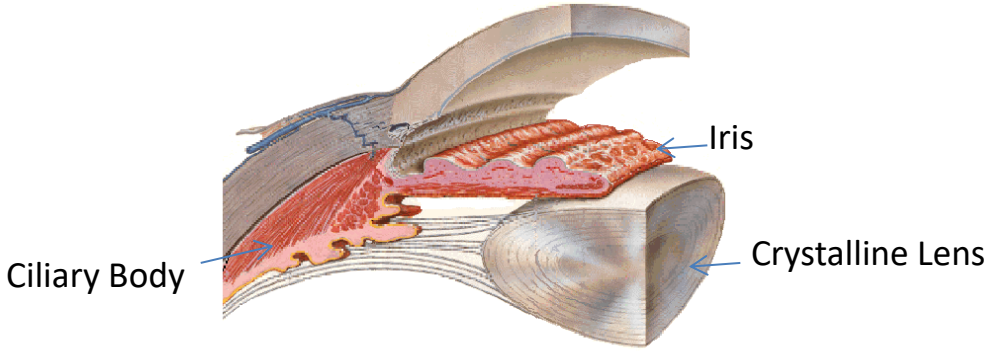

Iris

The iris is a thin flat vascular membrane having an average horizontal diameter of between 11 – 12 mm, and an average vertical diameter of between 9 – 11 mm. The iris acts as a diaphragm, like a shutter on a camera, regulating the amount of light that enters through the pupil. It is controlled by two muscles, the sphincter muscle and the dilator muscle, which constricts or dilates the pupil to allow varying amounts of light into the eye. The sphincter muscle lies around the very edge of the pupil. In bright light, the sphincter contracts, causing the pupil to constrict. The dilator muscle runs radially through the iris, like spokes on a wheel. This muscle dilates (enlarges the pupil) the eye in dim lighting or when caused to do so by a mydriatic drug.

The iris is flat and separates the anterior chamber from the posterior chamber, creating an angle.

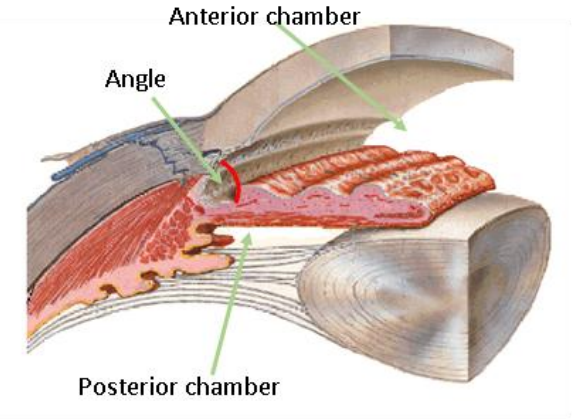

The iris is heavily pigmented with a brown pigment on the posterior surface that is distributed through the tissue unequally in different people. The amount and distribution of pigment in the iris determines the color of the eye. Blue eyes have the least amount of pigment, while brown eyes have the most. The iris is permeated by blood vessels. Its color comes from microscopic pigment cells called melanin.

Having the uniqueness of a fingerprint, each person has a distinct pattern of filaments, pits, and striations. Infants' eyes often change color as they become toddlers, but from this age forward, the iris color and pattern are stable throughout life. The iris is protected from external elements by the cornea. It is nourished and cushioned by the aqueous humor.

An inflammation of the iris is called iritis and can be seen as a flare with a slitlamp. In some cases of inflammation such as iritis, blockages can occur causing pupillary block glaucoma;

requiring the need to keep the eye dilated. The reason for the need to keep the eye dilated results from the swelling of the iris during the inflammation, which may cause the iris to swell back toward the crystalline lens, causing it to adhere to the lens; thus, the need to keep the eye dilated.

Pupil
The pupil is an opening called an aperture, through which light passes. It cannot be completely closed. It is positioned centrally and slightly nasally in the iris. Its minimum diameter in daylight is approximately 2 mm, and it may be dilated to approximately 9 mm. When external illumination is too bright to be endured without discomfort, the eyelids close automatically. While undilated, pupil diameters range from about 2 - 4 mm, but it is not uncommon to be seen as large as 7 mm or 8 mm in low light. Dilated, the pupil can be as large as 9 mm.

Pupil size is controlled by the muscles of the iris; the sphincter muscle, which constricts, and the dilator muscle, which dilates.

The pupil is smaller at birth and is largest at early childhood. The size diminishes with age. A difference in pupil size is called anisocoria. Approximately 17% of people have a difference of 1 mm or less. Approximately 4% of people have a pronounced difference in pupil size and should be referred for evaluations, as it could indicate pathological problems.

Inner Tunic

Retina
The retina is a transparent layer of tissue that forms the innermost lining of the globe. It is the light-sensitive tunic. Embryologically, the retina is an outgrowth of the brain. It is connected to the brain by the optic nerve, which is not really a nerve at all, but rather a tract. Any damage to the retina or optic nerve is considered permanent. The eyeball is designed around the retina. The sclera protects it and gives it shape, and the choroid nourishes it. It is held in place by the vitreous humor.

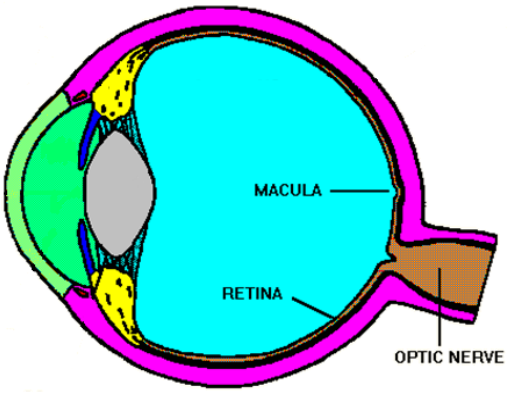

Retinal Cells
The retina consists of an outer pigmented layer and an inner nervous stratum or retina proper. The retinal layer consists mainly of nerve cells. The posterior two-thirds of the retina is called the visual portion because it is the surface on which images are focused by the cornea and the lens.

The retina is composed of an inner layer of nerve cells and an outer pigment epithelium that lies against the choroid. The base of the nerve cell layer contains two types of photoreceptor cells, namely rods and cones, each with a different function in the visual process. The rods are long slender cells that provide motion within the field and provide night vision or vision in low illumination. They are extremely sensitive to light. They are more numerous from the central to the front of the retina. They contain 600 to 1000 loosely stacked lamellae within a cell membrane. They contain photopigment rhodopsin. The molecules of rhodopsin lie within the membranes of lamellae. They contain organelles for producing energy and build-up of protein.

Cones are shorter cells that provide detail or fine vision. They also provide color vision. They are more numerous toward the posterior of the retina in the macula. There are only cones, (no rods) in the central fovea (located within the macula), which is where the greatest or fine vision occurs. Cones cells contain iodopsin and are not sensitive to small amounts of light. That is the reason for no color vision at night or in very low light conditions.

There are three categories of cones, according to the photopigments. One is most sensitive to short wavelengths or blue, one is most sensitive to green and one is most sensitive to longer wavelengths or red.

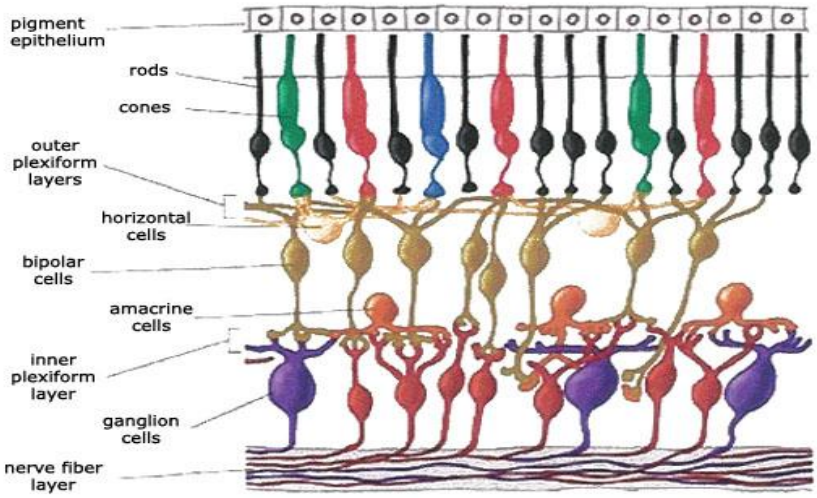

Retinal Metabolism and Visual Process
Retinal photoreceptors are sensitive to wavelengths from 380 nm to 750 nm.
In poor light, a person sees blue light better than red, which is why the ocular system tends to be more myopic, i.e., “twilight myopia”.

Anterior and Posterior Chambers

The anterior chamber is located between the back surface of the cornea and the iris. The posterior chamber is located between the back of the iris and the front surface of the crystalline lens. The ciliary processes produce and secrete the aqueous humor, which fills the anterior and posterior chambers, nourishing the back surface of the cornea and the front surface of the crystalline lens as well as removing waste products.

The aqueous flow having been produced by the ciliary process, enters the posterior chamber, nourishing the front surface of the crystalline lens, then passes through the pupil into the anterior chamber, where it nourishes the back surface of the cornea, removing waste products. It then drains through the canal of Schlemm, being filtered through the trabecular meshwork. The balance between the outflow and the production of aqueous maintains the intraocular pressure and is extremely important to the proper function of the eye. Increased intraocular pressure is associated with glaucoma. The anterior chamber depth varies with age, size of the eye, and whether cataract surgery has been performed.

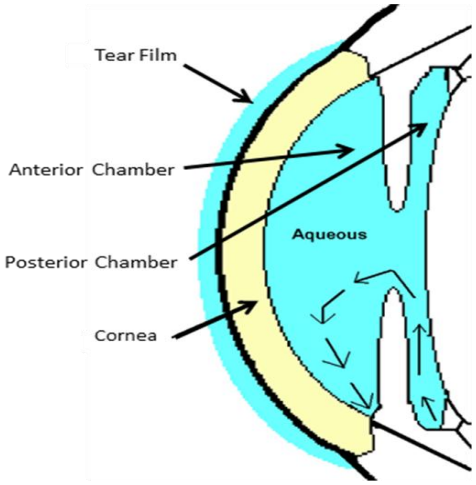

Vitreous Body

The vitreous body is located between the crystalline lens and the retina. The vitreous humor is a transparent gel that occupies the innermost part of the eye and supports the retina by providing nutrients to the retina by diffusion from the ciliary body. It maintains an attachment at the ora serrata and the optic disc. It is common for this attachment to weaken with age as the gel becomes less viscous with age, starting from back to front. A vitreous detachment can be considered a non-vision threatening occurrence, however, it should be monitored as if it can occasionally pull on the retina causing a retinal detachment, which IS sight-threatening. Symptoms of a vitreous detachment can include some of the same symptoms of a retinal detachment, including floaters, and flashes of light.

Floaters create shadows and are sloughed off material or debris in the vitreous. Sometimes increased by a vitreous detachment, they present as annoying, but unless they become so numerous or are in massive quantities in the visual axis, surgical removal of the vitreous is not particularly advised.

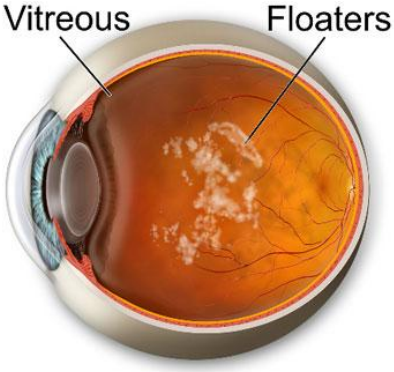

The Crystalline Lens

The crystalline lens is a biconvex, transparent, avascular body located between the vitreous humor and the back of the iris. It is semisolid, consisting of an elastic capsule surrounding the lens substance. Lens cells are formed throughout life, and new cells cover the old, forming layers that are onion-like in nature. It is made up of proteins and water. As it is avascular, it is nourished and oxygenated by diffusion from the aqueous humor.

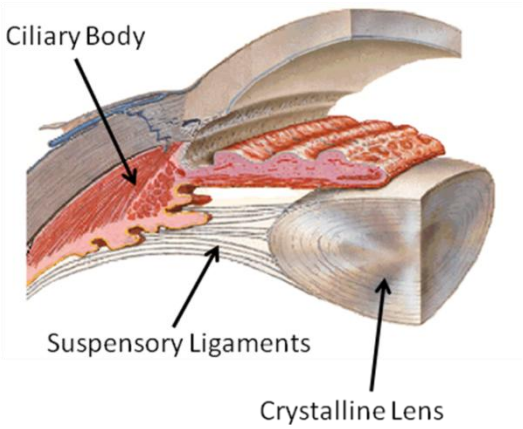

With an average index of refraction of approximately 1.42, the crystalline lens has between 15 – 20 diopters of power at rest. It performs about 1/3 of the refraction of the eye. At birth, the crystalline is almost entirely clear, while as it ages, it absorbs more UV and becomes more yellow.

The equatorial diameter is approximately 2/3 in children compared to adults. It is approximately 5 – 6 mm in children and increases to 9 – 10 mm in adults.

Because the lens continues to add cells, by about age 70, the nucleus comprises virtually the entire lens. The lens flattens with age and becomes harder. The lens is a relatively hydrated organ, approximately 66% water and 33% protein. The lens cortex is more hydrated than the lens nucleus.

Age-related changes of the crystalline lens include cataracts. They can be caused by several factors. Among them are age-related senile cataracts, which include cortical and nuclear cataracts and metabolic cataracts, which are diabetic-related or chemically caused such as by poisons or medications. A frequently discussed cataract is the UV-produced or sunshine

cataract. Congenital cataracts are caused prior to birth and are classified as birth defects. Sometimes they are caused by malnutrition of the mother or by rubella. Cataracts are seen frequently in third-world countries due to heat, poor hygiene, and poor water conditions, which cause chronic dehydration.

When a cataract obstructs vision to a sufficient degree, cataract removal is required. Cataract removal means removal of the crystalline lens. Cataract surgery has been significantly streamlined in recent years. With the absence of the crystalline lens (aphakia) approximately +15.00 to +20.00 D of refractive power is lost. In years past, it was necessary for a patient who had cataract surgery to either be fitted with cataract contact lenses or with cataract spectacles. Spectacles were/are bulky and vision is significantly compromised. Most often today, cataract patients have an intraocular implant (IOL) surgically implanted within the eye to replace the loss of the natural lens. Pseudophakia is the term used to describe the result of the removal of the natural crystalline lens and implantation of an intraocular replacement lens (IOL).

Approximately 60% of humans have some alteration in lens transparency after 65 years of age. Progression of lens changes differs among individuals, and lens opacities can cause visual deficits in a shorter or longer period of time.

Accommodative Anatomy
Included in accommodation are the crystalline lens, the ciliary body, and the zonules of Zinn, which are suspensory ligaments. The lens is suspended from the ciliary process by the zonules.

Accommodation occurs when the brain recognizes a blurred image. The ciliary muscle contracts and moves toward the crystalline lens, the zonule fibers relax and the crystalline lens bulges or becomes more convex, allowing more plus power to be affected. The lens becomes thinner following the relaxation of the ciliary muscle.

The axial thickness changes with the state of accommodation. Between 30 to 35 years of age, the nucleus of the crystalline lens starts turning yellow to yellow-brown and becomes larger. The amplitude of accommodation is about 15 diopters at birth and diminishes to virtually zero by the age of 61. The cells of the crystalline lens continue to grow, while the capsule remains the same. This hardening of the lens causes presbyopia.

Presbyopia is defined as loss of accommodation of the crystalline lens.

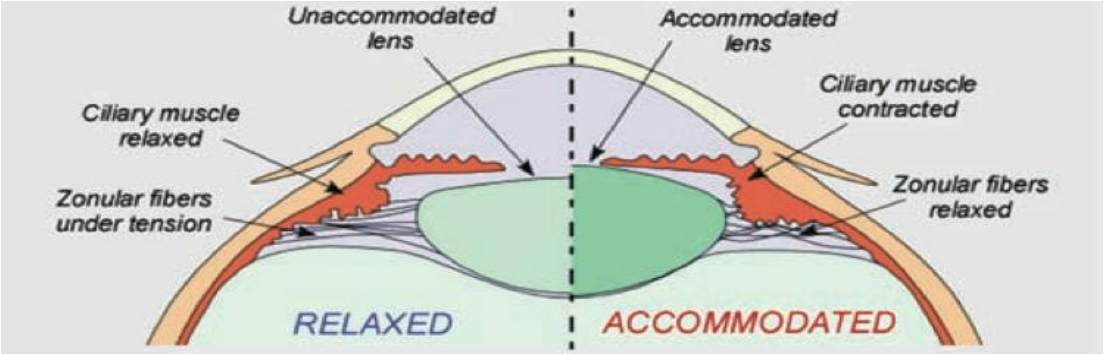

Extraocular Muscles

Rectus means "straight". There are four rectus or "straight" extraocular muscles. Oblique means "slanting". There are only two oblique or "slanting" extraocular muscles.
There are six extraocular muscles. While there are primary functions of each muscle, each muscle works as a partner to another muscle.

These are the primary functions of each muscle:

- Superior Rectus - Moves the eye up
- Superior Oblique - Rotates the eye so that the top of the eye moves toward the nose
- Medial Rectus - Moves eye toward nose
- Lateral Rectus - Moves eye away from nose
- Inferior Rectus - Moves the eye down
- Inferior Oblique - Rotates the eye so that the top of the eye moves away from the nose

Let's think for a moment; if the superior rectus attempts to move the eye up, that means that it contracts to do so. While it contracts, the opposite muscle, the inferior rectus muscle must relax for the function to occur. If one or the other muscle is weak, the eye will have a muscle "imbalance" and the function may not occur. We'll discuss this a little more, later.

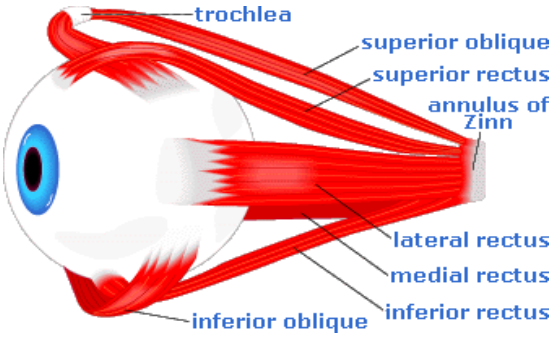

Ocular Movements

- Abduction – eye moves temporally
- Adduction – eye moves nasally
- Elevation – eye moves up
- Depression – eye moves down
- Intorsion –top of the cornea rotates toward the nose
- Extorsion – top of the cornea rotates away from the nose
- Convergence – both eyes move nasally at the same time
- Divergence – both eyes move temporally at the same time

Diplopia

Diplopia is defined as double vision. It is the perception of two images from a single image. Rarely, it may occur in one eye only (monocular), but more commonly in an abnormal positioning of the two eyes in relation to each other. A double image is seen by the brain caused by a muscular imbalance in one or more muscles of the eye overcoming the brain's desire for fusion. The illustration below demonstrates a vertical muscle imbalance, creating two lines of print.

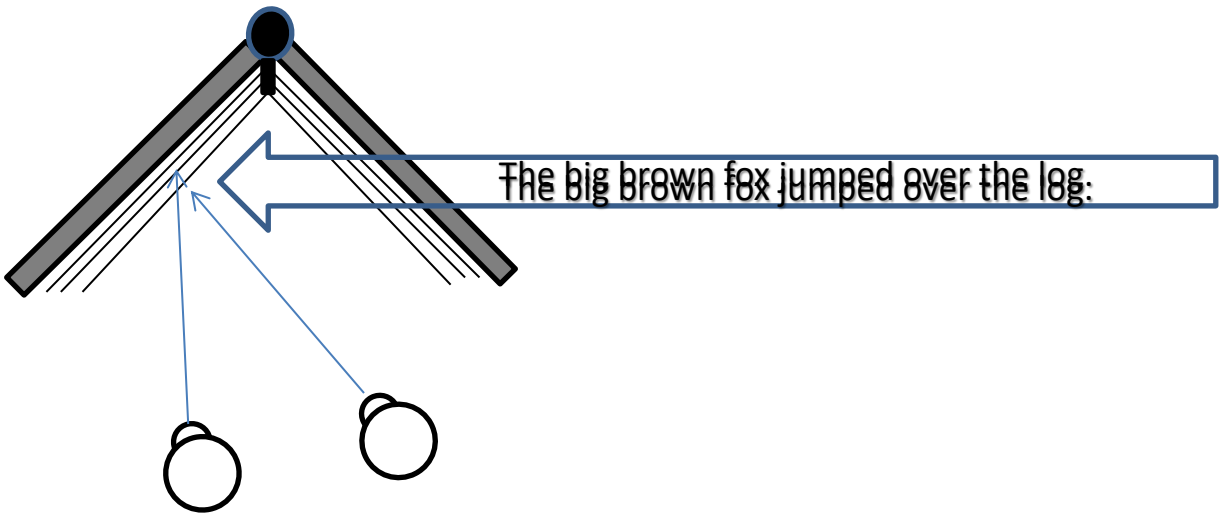

Tonicity

Tonicity - The state of slight contraction of all six extraocular muscles of the eye while at rest to hold the eye steady in a fixed position.

Tonicity is defined as the state of healthy tension or partial contraction of muscle fibers while at rest; tone; tonus.

Fusion

Fusion - The ability of the brain to form a single image by coordinating the movements of the two eyes so that the visual images fall on corresponding areas of the retinas of the two eyes.

Fusion is defined as the cortical integration of the images received simultaneously by the two eyes. It is the function of merging simultaneous bilateral retinal images into a single perceptual image, sensory fusion.

Muscle Imbalances – Terminology

- Orthophoria - ortho (correct) + phoria (carrying)

    - Eyes that are “carried correctly”
    - Proper extraocular muscle tonicity is maintained
    - Fusion takes place because an image is formed on corresponding points of each retina.
- Heterotropia -hetero (different) + tropia (turning)
    - Turning in different directions
    - Strabismus, squint, crossed-eyes
    - Eccentric fixation occurs when the non-fixating eye is turned in another direction, thus retinal images fall on non-corresponding points of each retina.
- Strabismus - a disorder in which the two eyes are not correctly aligned. If untreated it can lead to amblyopia - also called "lazy eye" - a condition in which the vision in one eye deteriorates. Strabismus and amblyopia are together the most common causes of visual impairment in children.

Strabismus, more commonly known as crossed-eyes, is a vision condition in which a person cannot align both eyes simultaneously under normal conditions. One or both eyes may turn in, out, up, or down. An eye turn may be constant (when the eye turns all of the time) or intermittent (turning only some of the time, such as, under stressful situations or when ill). Whether constant or intermittent, strabismus always requires appropriate evaluation and treatment.

Terminology for muscle imbalances is by identifying the prefix and suffix. Simply put the prefix and suffix together to identify the term.

- Eso - Turning in
- Exo - Turning out
- Hyper - above - up
- Hypo - below - down
- -phoria - tendency to turn
- -tropia - definite turning

Tropias

Esotropia (Cross-eyes) is defined as a misalignment of the eyes in which one or, less commonly, both eyes turn inward or nasally, particularly seen with hypermetropia. It is also referred to as a convergent squint. The eye has a definite turning in. It is sometimes referred to as Boss-eyed.

Exotropia is defined as divergent strabismus. Turning laterally or temporally of one, or rarely, both eyes. It is a definite turning out of one or both eyes. It is also sometimes referred to as Wall eyes.

Hypertropia is defined as an upward deviation of one eye while the other eye remains straight and fixates normally. It is a definite vertical turning upward of one eye.

Hypotropia is defined as a downward deviation of one eye. It is a definite vertical turning down of one eye.

Phorias

- Esophoria - A tendency of the eye to turn in
- Exophoria - A tendency of the eye to turn out
- Hyperphoria - A tendency of the eye to turn up
- Hypophoria - A tendency of the eye to turn down

COPYRIGHT 2025 by the National Academy of Opticianry. All rights reserved. This book, or parts thereof, may not be reproduced in any form or by any means, electronic or mechanical, including photocopy, recording, or any information storage and retrieval system now known or to be invented, transmitted in any form or by any means electronic or mechanical without the expressed prior written permission of the copyright owner. For information, please contact the National Academy of Opticianry, 8401 Corporate Drive #605, Landover, MD 20785.